

# Robib *Telemedicine* Clinic

## Preah Vihear Province

### S E P T E M B E R 2 0 1 4

Report and photos compiled by Rithy Chau and Peng Sovann, SHCH Telemedicine

On Monday, September 1, 2014, SHCH staffs PA Rithy, Driver and Nurse Peng Sovann traveled to Preah Vihear for the monthly Robib Telemedicine (TM) Clinic.

The following two days, Tuesday and Wednesday (mornings), September 2 & 3, 2014, the Robib TM Clinic opened to receive the patients for evaluations. There were 7 new cases seen during this month, and the patients were examined and their data were transcribed along with digital pictures of the patients, then transmitted and received replies from their TM CCH/MGH in Boston and Phnom Penh on Wednesday and Thursday, September 3 & 4, 2014.

On Thursday, replies from SHCH in Phnom Penh and CCH/MGH Telemedicine in Boston were downloaded. Per advice from Boston, SHCH and PA Rithy on site, Nurse Sovann managed and treated the patients accordingly. There were also patients who came for brief consult and refills of medications. Finally, the data of the patient concerning final diagnosis and treatment/management would then be transcribed and transmitted to Nurse Sovann Peng at SHCH who compiled and sent for website publishing.

The followings detail e-mails and replies to the medical inquiries communicated between Robib TM Clinic and their TM CCH/MGH in Phnom Penh and Boston:

**From:** [Robib Telemedicine](#)

**To:** [Rithy Chau](#) ; [Kruy Lim](#) ; [Cornelia Haener](#) ; [Kathy Fiamma](#) ; [Paul Heinzelmann](#) ; [Joseph Kvedar](#)

**Cc:** [Bernie Krisher](#) ; [Jason Reinhardt](#) ; [Thero So Nourn](#) ; [Laurie & Ed Bachrach](#) ; [Robib School 1](#)

**Sent:** Monday, August 25, 2014 11:02 AM

**Subject:** Schedule for Robib TM Clinic September 2014

Dear all,

I would like to inform you that there will be Robib TM Clinic in September 2014 which starts from September 1 to 5, 2014.

The agenda for the trip is as following:

1. On Monday September 1, 2014, we will be starting the trip from Phnom Penh to Rovieng, Preah Vihear province.
2. On Tuesday September 2, 2014, the clinic opens to see the patients for the whole morning then the patients' information will be typed up into computer as the word file and sent to both partners in Boston and Phnom Penh.
3. On Wednesday September 3, 2014, the activity is the same as on Tuesday
4. On Thursday September 4, 2014, download all the answers replied from both partners then treatment plan will be made accordingly and prepare the medicine for the patients in the afternoon.
5. On Friday September 5, 2014, Draw blood from patients for lab test at SHCH then come back to Phnom Penh.

Thank you very much for your cooperation and support in the project.

Best regards,  
Sovann

**From:** [Robib Telemedicine](#)  
**To:** [Cornelia Haener](#) ; [Rithy Chau](#) ; [Kruy Lim](#) ; [Kathy Fiamma](#) ; [Paul Heinzelmann](#) ; [Joseph Kvedar](#)  
**Cc:** [Bernie Krisher](#) ; [Jason Reinhardt](#) ; [Thero So Nourn](#) ; [Laurie & Ed Bachrach](#)  
**Sent:** Tuesday, September 02, 2014 3:22 PM  
**Subject:** Robib TM Clinic September 2014, Case#1, Pheng Sopheara, 16M

Dear all,

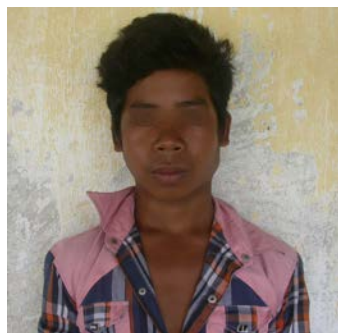There are four new cases for the first day of Robib TM clinic September 2014. This is case number 1, Pheng Sopheara, 16M and photos.

Best regards,  
Sovann

## Robib Telemedicine Clinic

Sihanouk Hospital Center of HOPE and Center for Connected Health  
Rovieng Commune, Preah Vihear Province, Cambodia

### History and Physical



**Name/Age/Sex/Village:** Pheng Sopheara, 16M (Bos Pey Village)

**Chief Complaint (CC):** Left lateral neck mass x two weeks

**History of Present Illness (HPI):** 16M presented with a small pustular lesion on the posterior of lobule of the left ear and he broke it by his finger nail. The lesion became infected with discharge, mild pain and low grade fever, he got took two kinds of medicine (unknown name) bought from local pharmacy, taking bid. Several days later, he noticed a lump on left side of the neck with swelling, warmth and pain, but the fever has gone. He finished the medicine several days. He denied insect bite.

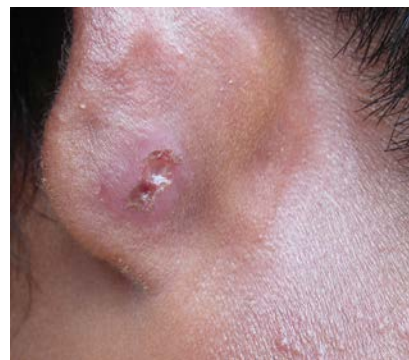**Past Medical History (PMH):** Unremarkable

**Family History:** None

**Social History:** Stopped study two years and help family doing farming, no cig smoking; Casual EtOH

**Current Medications:** None

**Allergies:** NKDA



**Review of Systems (ROS):** Unremarkable

**PE:**

**Vital sign:** BP: 113/79 P: 79 R: 20 T: 36.5°C Wt: 48Kg

**General:** look stable

**HEENT:** Small wound on posterior to left ear lobule with discharge, no bad smell. LN enlargement about 3x4cm on left side of the neck, tender on palpable, with papular lesion on the surface, mobile, regular border; Ear canal cannot be seen both sides due to ear wax; no oropharyngeal lesion, pink conjunctiva.

**Chest:** CTA bilaterally, no rales, no rhonchi; Heart: RRR, no murmur

**Abd:** Soft, no tender, no distension, (+) BS, no HSM, no surgical scar

**Extremities/Skin:** No legs edema, no skin lesion

**MS/Neuro:** MS +5/5, motor and sensory intact, DTRs +2/4, normal gait

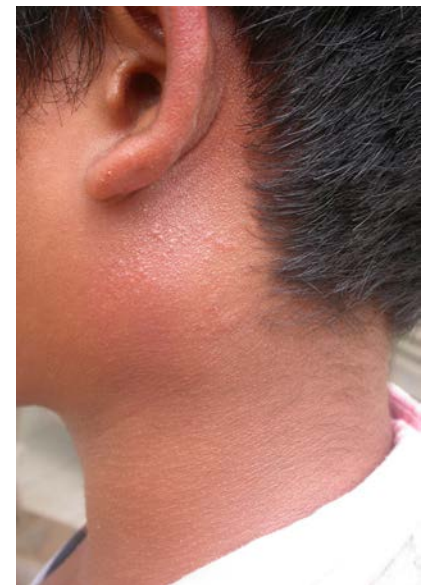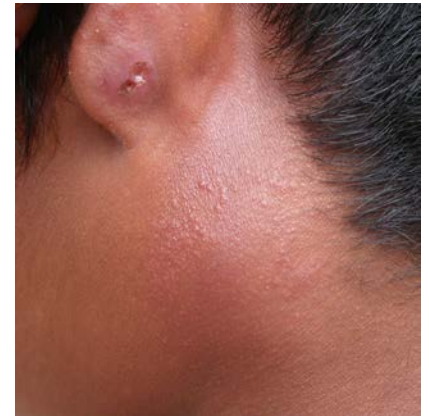**Lab/study:** None

**Assessment:**

1. Infected wound on left ear lobule
2. Cellulitis
3. PTB??

**Plan:**

1. Augmentin 625mg 1t po tid x 7days
2. Ibuprofen 200mg 3t po tid for 5days
3. Clean the wound with NSS qd
4. If not better in one week, suggest to refer for further evaluation and management



Labs available locally: Hemoglobin, UA, Glucose, Stool Occult Blood, and Pregnancy Test

**Specific Comments/Questions for Consultants:** Do you agree with my assessment and plan?

**Examined by:** Nurse Sovann Peng

**Date:** September 2, 2014

Please send all replies to [robibtelemed@gmail.com](mailto:robibtelemed@gmail.com) and cc: to [rithychau.sihosp@gmail.com](mailto:rithychau.sihosp@gmail.com)

*The information transmitted in this e-mail is intended only for the person or entity to which it is addressed and may contain confidential and/or privileged material. Any review, retransmission, dissemination or other use of or taking of any action in reliance upon, this information by persons or entities other than the intended recipient is prohibited. If you received this e-mail in error, please contact the sender and delete material from any computer.*

**From:** [Cornelia Haener](#)

**To:** '[Robib Telemedicine](#)'; '[Rithy Chau](#)'; '[Kruy Lim](#)'; '[Kathy Fiamma](#)'; '[Paul Heinzelmann](#)'; '[Joseph Kvedar](#)'

**Cc:** '[Bernie Krisher](#)'; '[Jason Reinhardt](#)'; '[Thero So Nourn](#)'; '[Laurie & Ed Bachrach](#)'

**Sent:** Tuesday, September 02, 2014 6:53 PM

**Subject:** RE: Robib TM Clinic September 2014, Case#1, Pheng Sopheara, 16M

Dear Sovann,

Thanks for submitting this case. Is it possible to get a specimen for culture? Any fluctuant area you could puncture?

One important Ddx would be Melioidosis. We have had a similar case in an 11-year old boy in Kampot.

Augmentin is a good AB to start.

Kind regards

Cornelia

**From:** [Cusick, Paul S.,M.D.](#)

**To:** [Fiamma, Kathleen M.](#) ; '[robibtelemed@gmail.com](mailto:robibtelemed@gmail.com)'

**Cc:** '[rithychau.sihosp@gmail.com](mailto:rithychau.sihosp@gmail.com)'

**Sent:** Friday, September 05, 2014 11:50 PM

**Subject:** RE: ROBIB TM Clinic September 2014, Case#1, Pheng Sopheara, 16M

Thank you for the opportunity to consult on this case.

Review history and examination and the photographs, and appears to be has a cellulitis of the left ear with an enlarged regional lymph node. This is the expected with an infection in the ear. I think that your treatment with Augmentin and local wound cleaning is appropriate. If he has enlarged lymph nodes in other locations on his body, I would consider expanding the possibilities to include lymphatic disease or cancers.

However, I expect that he'll improve with the treatment that you're giving him once the infection is resolved.

Thank you for the opportunity. I wish you the best of luck.

---

**From:** [Robib Telemedicine](#)

**To:** [Rithy Chau](#) ; [Kruy Lim](#) ; [Kathy Fiamma](#) ; [Paul Heinzelmann](#) ; [Joseph Kvedar](#) ; [Cornelia Haener](#)

**Cc:** [Bernie Krisher](#) ; [Jason Reinhardt](#) ; [Thero So Nourn](#) ; [Laurie & Ed Bachrach](#)

**Sent:** Tuesday, September 02, 2014 3:24 PM

**Subject:** Robib TM Clinic September 2014, Case#2, Chum Chet, 74F

Dear all,

This is case number 2, Chum Thet, 74F and photos.

Best regards,

Sovann

# Robib Telemedicine Clinic

Sihanouk Hospital Center of HOPE and Center for Connected Health  
Rovieng Commune, Preah Vihear Province, Cambodia

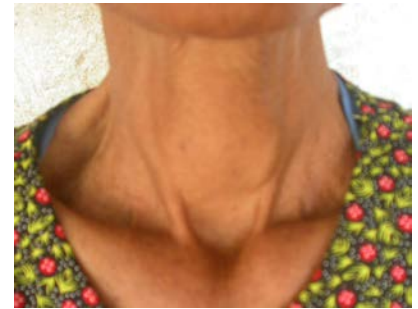## History and Physical



**Name/Age/Sex/Village:** Chum Thet, 74F (Somrith Village)

**Chief Complaint (CC):** Neck mass x 30years

**History of Present Illness (HPI):** 74F, farmer, noticed a neck mass after she delivered the third baby but denied of any symptoms. In these few years, she presented with symptoms of palpitation, heat intolerance, tremor, insomnia, hair loss and weight loss. She went to consult at referral hospital for three times and was admitted for several days, and treated with IV fluid and IM injection medicine (unknown name) but she noticed the symptoms still persisted. Her last admission to hospital was six months. She denied of cough, SOB, vomiting, bloody/black stool, dysuria, oliguria.



**Past Medical History (PMH):** Unremarkable

**Family History:** No family member with Goiter, HTN, or DMII

**Social History:** Chewing tobacco, no cig smoking; no EtOH

**Current Medications:** None

**Allergies:** NKDA

**Review of Systems (ROS):** Unremarkable

**PE:**

**Vital sign:** BP: Lt 161/91, Rt 154/82 P: 87 R: 18 T: 36°C Wt: 35Kg

**General:** look stable

**HEENT:** Mass about 4x5cm on anterior neck, soft, regular border, no tender, no bruit; no neck LN palpable, no oropharyngeal lesion, pink conjunctiva

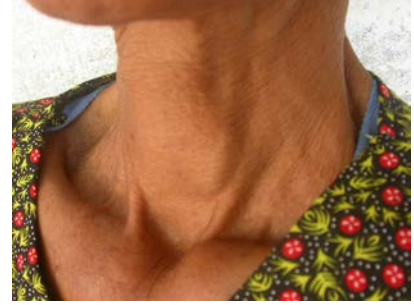**Chest:** CTA bilaterally, no rales, no rhonchi; Heart: RRR, no murmur

**Abd:** Soft, no tender, no distension, (+) BS, no HSM, no surgical scar

**Extremities/Skin:** No legs edema, no skin lesion, positive right dorsalis pedis and posterior tibial pulse

**MS/Neuro:** MS +5/5, motor and sensory intact, DTRs +2/4, normal gait

**Lab/study:** None



**Assessment:**

1. Goiter
2. Hypertension

**Plan:**

1. Draw blood for Lyte, Creat, TSH and Free T4 at SHCH
2. Do regular exercise, eat low fats diet
3. Recheck the BP next day, if still elevated over 140/90, start HCTZ 25mg 1t po qd

Labs available locally: Hemoglobin, UA, Glucose, Stool Occult Blood, and Pregnancy Test

**Specific Comments/Questions for Consultants: Do you agree with my assessment and plan?**

**Examined by:** Nurse Sovann Peng

**Date:** September 2, 2014

Please send all replies to [robibtelemed@gmail.com](mailto:robibtelemed@gmail.com) and cc: to [rithychau.sihosp@gmail.com](mailto:rithychau.sihosp@gmail.com)

*The information transmitted in this e-mail is intended only for the person or entity to which it is addressed and may contain confidential and/or privileged material. Any review, retransmission, dissemination or other use of or taking of any action in reliance upon, this information by persons or entities other than the intended recipient is prohibited. If you received this e-mail in error, please contact the sender and delete material from any computer.*

**From:** [Cornelia Haener](#)

**To:** ['Robib Telemedicine'](#) ; ['Rithy Chau'](#) ; ['Kruy Lim'](#) ; ['Kathy Fiamma'](#) ; ['Paul Heinzelmann'](#) ; ['Joseph Kvedar'](#)

**Cc:** ['Bernie Krisher'](#) ; ['Jason Reinhardt'](#) ; ['Thero So Nourn'](#) ; ['Laurie & Ed Bachrach'](#)

**Sent:** Tuesday, September 02, 2014 6:55 PM

**Subject:** RE: Robib TM Clinic September 2014, Case#2, Chum Chet, 74F

Dear Sovann,

Thanks for submitting this case. I agree with assessment and plan.

Kind regards

Cornelia

**From:** [Barbesino, Giuseppe, M.D.](#)

**To:** [Fiamma, Kathleen M.](#)

**Cc:** ['rithychau@sihosp.org'](mailto:rithychau@sihosp.org) ; ['ROBIB'](#)

**Sent:** Thursday, September 04, 2014 7:58 PM

**Subject:** RE: Robib TM Clinic September 2014, Case#2, Chum Chet, 74F

Hello: I agree that hyperthyroidism needs to be ruled out, if at all possible a neck ultrasound to clarify whether the mass is cystic or not would be important. Since her HR is not very high however, I would also check CBC as anemia can cause palpitations.

Giuseppe Barbesino, M.D.

Thyroid Associates - Thyroid Unit



**From:** [Robib Telemedicine](#)

**To:** [Kruy Lim](#) ; [Kathy Fiamma](#) ; [Paul Heinzelmann](#) ; [Joseph Kvedar](#) ; [Cornelia Haener](#) ; [Rithy Chau](#)

**Cc:** [Bernie Krisher](#) ; [Jason Reinhardt](#) ; [Thero So Nourn](#) ; [Laurie & Ed Bachrach](#)

**Sent:** Tuesday, September 02, 2014 3:25 PM

**Subject:** Robib TM Clinic September 2014, Case#3, Em Vin, 56F

Dear all,

This is case number 3, Em Vin, 56F and photos.

Best regards,  
Sovann

## Robib Telemedicine Clinic

Sihanouk Hospital Center of HOPE and Center for Connected Health  
Rovieng Commune, Preah Vihear Province, Cambodia

### History and Physical



**Name/Age/Sex/Village:** Em Vin, 56F (Koh Pon Village)

**Chief Complaint (CC):** Neck mass x 1year

**History of Present Illness (HPI):** 56F, farmer, presented with symptoms of tremor, palpitation, insomnia, weight loss and noticed a lump on the anterior of the neck. She denied of fever, cough, diaphoresis, syncope, dysphagia. She has normal appetite, normal bowel movement, normal urination. She never seeks medical consultation or other treatment.

**PMH/PSH:** Cholecystectomy in Kg Thom referral hospital in 2008

**Family History:** No family member with Goiter, HTN, or DMII

**Social History:** Chewing tobacco, no cig smoking; no EtOH

**Current Medications:** None

**Allergies:** NKDA

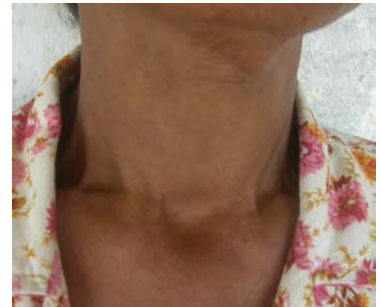**Review of Systems (ROS):** 15 years post menopause; Both knee joint pain without swelling, stiffness, erythema for 1 year.

**PE:**

**Vital sign:** BP: 136/85 P: 100 R: 18 T: 36.3°C Wt: 49Kg

**General:** look stable

**HEENT:** Mass about 5x6cm on anterior neck, soft, regular border, no tender, no bruit; no neck LN palpable, no oropharyngeal lesion, pink conjunctiva



**Chest:** CTA bilaterally, no rales, no rhonchi; Heart: RRR, no murmur

**Abd:** Soft, no tender, no distension, (+) BS, no HSM, no surgical scar

**Both knee exam:** no swelling, no erythema, no stiffness, no deformity

**MS/Neuro:** MS +5/5, motor and sensory intact, DTRs +2/4, normal gait

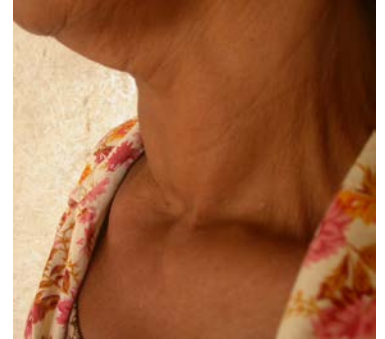**Lab/study:** None

**Assessment:**

1. Goiter
2. Osteoarthritis

**Plan:**

1. Draw blood for TSH and Free T4 at SHCH
2. Paracetamol 500mg 1-2tab po qid prn pain
3. Do regular exercise, eat low fats diet



Labs available locally: Hemoglobin, UA, Glucose, Stool Occult Blood, and Pregnancy Test

**Specific Comments/Questions for Consultants:** Do you agree with my assessment and plan?

**Examined by:** Nurse Sovann Peng

**Date:** September 2, 2014

Please send all replies to [robibtelemed@gmail.com](mailto:robibtelemed@gmail.com) and cc: to [rithychau.sihosp@gmail.com](mailto:rithychau.sihosp@gmail.com)

*The information transmitted in this e-mail is intended only for the person or entity to which it is addressed and may contain confidential and/or privileged material. Any review, retransmission, dissemination or other use of or taking of any action in reliance upon, this information by persons or entities other than the intended recipient is prohibited. If you received this e-mail in error, please contact the sender and delete material from any computer.*

**From:** [Cornelia Haener](#)

**To:** ['Robib Telemedicine'](#) ; ['Kruy Lim'](#) ; ['Kathy Fiamma'](#) ; ['Paul Heinzelmann'](#) ; ['Joseph Kvedar'](#) ; ['Rithy Chau'](#)

**Cc:** ['Bernie Krisher'](#) ; ['Jason Reinhardt'](#) ; ['Thero So Nourn'](#) ; ['Laurie & Ed Bachrach'](#)

**Sent:** Tuesday, September 02, 2014 6:58 PM

**Subject:** RE: Robib TM Clinic September 2014, Case#3, Em Vin, 56F

Dear Sovann,

Thanks for submitting this case. Does she have signs of hyperthyroidism when you examine her? Any tremor, sweaty hands, hyperactive reflexes? If yes, I suggest giving her a Beta-blocker while waiting for the lab results to come back. You write that her pulse rate is 100/min.

Kind regards

Cornelia

**From:** [Barbesino, Giuseppe,M.D.](#)

**To:** [Fiamma, Kathleen M.](#) ; [rithychau@sihosp.org](mailto:rithychau@sihosp.org) ; [ROBIB](#)

**Sent:** Thursday, September 04, 2014 8:52 PM

**Subject:** RE: Robib TM Clinic September 2014, Case#3, Em Vin, 56F



I agree with the plan, this lady may have hyperthyroidism given goiter and tachycardia, however I would also recommend cbc.

Giuseppe Barbesino, M.D.  
Thyroid Associates - Thyroid Unit

---

**From:** [Robib Telemedicine](#)  
**To:** [Kathy Fiamma](#) ; [Paul Heinzelmann](#) ; [Joseph Kvedar](#) ; [Rithy Chau](#) ; [Kruy Lim](#)  
**Cc:** [Bernie Krisher](#) ; [Jason Reinhardt](#) ; [Thero So Nourn](#) ; [Laurie & Ed Bachrach](#)  
**Sent:** Tuesday, September 02, 2014 3:34 PM  
**Subject:** Robib TM Clinic September 2014, Case#4, Kong Keum, 78M

Dear all,

This is last case for the first day of Robib TM Clinic September 2014. Case number 4, Kong Keum, 78M and photos. Please wait for other cases which will be sent to you tomorrow.

Thank you very much for your cooperation and support in this project.

Best regards,  
Sovann

## Robib Telemedicine Clinic

Sihanouk Hospital Center of HOPE and Center for Connected Health  
Rovieng Commune, Preah Vihear Province, Cambodia

### History and Physical



**Name/Age/Sex/Village:** Kong Keum, 78M (Rovieng Tbong Village)

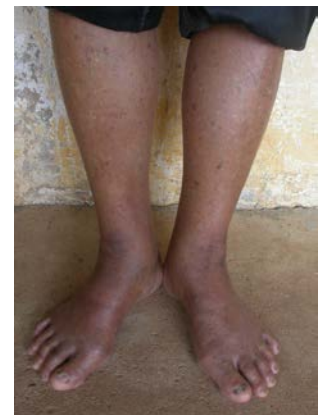**Chief Complaint (CC):** SOB x 4 months

**History of Present Illness (HPI):** 78M, farmer, presented with symptoms of SOB which frequently occurred in early morning (1 – 4 AM) and wake him up and got better with sit up. He noticed he needed to sleep on few pillows to make him less SOB. It also associated with fever, and palpitation, but denied cough, chest pain, diaphoresis, syncope, edema, oliguria. On April 24, 2014, He went to provincial referral hospital and admitted there for two weeks. He reported that doctor told that he had lung and heart disease. He got treatment with IV fluid and IM injection and he noticed of legs edema, abdominal distension. On discharge, he was prescribed with Enalapril 5mg 1t po qd and Furosemide 40mg 1/2t po bid.

**Past Medical History (PMH):** Unremarkable

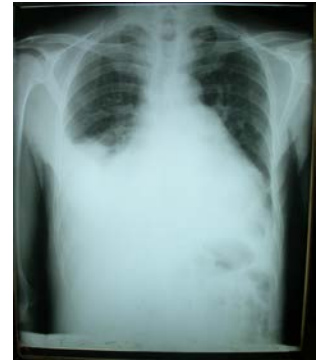**Family History:** No family member with HTN, DMII, or PTB

**Social History:** Smoking 1pack of cig per day for over 20yrs; casual EtOH; stopped both for 20yrs



**Current Medications:**

- 1. Enalapril 5mg 1t po qd
- 2. Furosemide 40mg 1/2t po bid



**Allergies:** NKDA

**Review of Systems (ROS):** No vomiting, no hematemesis, no bloody/black stool, no dysuria, no oliguria

**PE:**

**Vital sign:** BP: 96/77 P: 87 R: 22 T: 36°C O2sat:93% RA Wt: 53Kg

**General:** look sick, full alert

**HEENT:** No oropharyngeal lesion, pink conjunctiva, no thyroid enlargement, no neck LN palpable, no JVD

**Chest:** Bilateral coarse crackle; Heart: irregular rhythm (prolong duration of beating after two beats), regular rate, no murmur

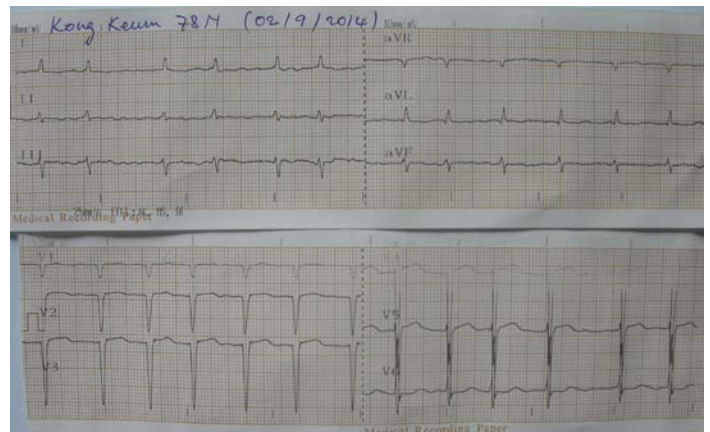
**Abd:** Soft, no tender, mild distension, (+) BS, no HSM, no surgical scar

**Extremities/Skin:** 2+ Legs edema, no skin lesion, positive right dorsalis pedis and posterior tibial pulse

**MS/Neuro:** MS +5/5, motor and sensory intact, DTRs +2/4, normal gait

**Lab/study:**

- RBS: 136mg/dl
- EKG attached
- CXR (done on April 24, 2014)



**Assessment:**

- 1. CHF
- 2. Pleural effusion

**Plan:**

- 1. Keep the same above treatment
- 2. Drink only 1000 – 1500mL water per day
- 3. Refer to Phnom Penh tomorrow for further evaluation and management

Labs available locally: Hemoglobin, UA, Glucose, Stool Occult Blood, and Pregnancy Test

**Specific Comments/Questions for Consultants:** Do you agree with my assessment and plan?

**Examined by:** Nurse Sovann Peng

**Date:** September 2, 2014

Please send all replies to [robibtelemed@gmail.com](mailto:robibtelemed@gmail.com) and cc: to [rithychau.sihosp@gmail.com](mailto:rithychau.sihosp@gmail.com)

*The information transmitted in this e-mail is intended only for the person or entity to which it is addressed and may contain confidential and/or privileged material. Any review, retransmission, dissemination or other use of or taking of any action in reliance upon, this information by persons or entities other than the intended recipient is prohibited. If you received this e-mail in error, please contact the sender and delete material from any computer.*

From: Fang, Leslie S., M.D.  
Sent: Thursday, September 04, 2014 9:12 AM  
To: Fiamma, Kathleen M.  
Cc: Fang, Leslie S., M.D.  
Subject: Re: Robib TM Clinic September 2014, Case#4, Kong Keum, 78M

Agree that the patient has congestive heart failure with borderline blood pressure and residual fluid overload.

He would benefit from further cardiac evaluation.

Needs to stop smoking.

Leslie Fang, MD

---

**From:** [Robib Telemedicine](#)  
**To:** [Cornelia Haener](#) ; [Kathy Fiamma](#) ; [Paul Heinzelmann](#) ; [Joseph Kvedar](#) ; [Rithy Chau](#) ; [Kruy Lim](#)  
**Cc:** [Bernie Krisher](#) ; [Jason Reinhardt](#) ; [Thero So Nourn](#) ; [Laurie & Ed Bachrach](#)  
**Sent:** Wednesday, September 03, 2014 1:58 PM  
**Subject:** Robib TM Clinic September 2014, Case#5, Preab Thinn, 55F

Dear all,

There are three new cases for second day of Robib TM clinic September 2014. This is case number 5, continued from Yesterday, Preab Thinn, 55F and photos.

Best regards,  
Sovann

## **Robib Telemedicine Clinic**

**Sihanouk Hospital Center of HOPE and Center for Connected Health**  
Rovieng Commune, Preah Vihear Province, Cambodia

### **History and Physical**



**Name/Age/Sex/Village:** Preab Thinn, 55F (Sre Thom Village)

**Chief Complaint (CC):** Neck mass x 17years

**History of Present Illness (HPI):** 55F, farmer, presented with a thump size mass on the anterior of the neck without any symptoms until the last three years, when she developed palpitation, heat intolerance, tremor and

insomnia. She went to consult at provincial referral hospital and was advised to seek further evaluation at Phnom Penh but she was not able to go there. She denied of cough, SOB, syncope, diaphoresis, bloody/mucus stool, weight loss, edema.

**Past Medical History (PMH):** Unremarkable

**Family History:** No family member with Goiter, HTN, or DMII

**Social History:** No cig smoking; no EtOH

**Current Medications:** None

**Allergies:** NKDA

**Review of Systems (ROS):** Two years post menopause

**PE:**

**Vital sign: BP: 121/98 P: 98 R: 18 T: 36°C Wt: 41Kg**

**General:** look stable

**HEENT:** Mass about 4x5cm on anterior neck, soft, smooth, regular border, no tender, no bruit; no neck LN palpable, no oropharyngeal lesion, pink conjunctiva

**Chest:** CTA bilaterally, no rales, no rhonchi; Heart: RRR, no murmur

**Abd:** Soft, no tender, no distension, (+) BS, no HSM, no surgical scar

**Extremities/Skin:** No legs edema, no skin lesion

**MS/Neuro:** MS +5/5, motor and sensory intact, DTRs +2/4, normal gait

**Lab/study:** None

**Assessment:**

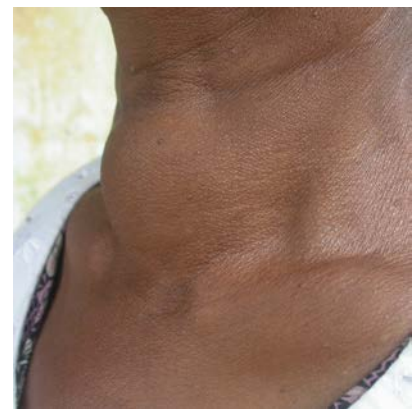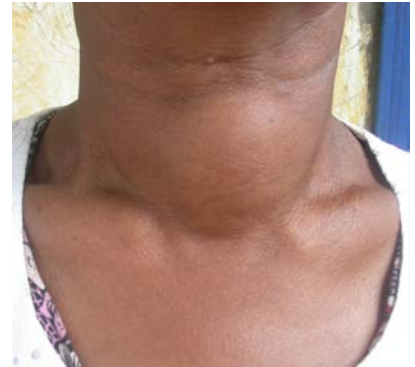1. Diffuse goiter
2. Thyroid cyst??

**Plan:**

1. Draw blood for TSH and Free T4 at SHCH

**Labs available locally:** Hemoglobin, UA, Glucose, Stool Occult Blood, and Pregnancy Test

**Specific Comments/Questions for Consultants:** Do you agree with my assessment and plan?



**Examined by: Nurse Sovann Peng**

**Date: September 3, 2014**

Please send all replies to [robibtelemed@gmail.com](mailto:robibtelemed@gmail.com) and cc: to [rithychau.sihosp@gmail.com](mailto:rithychau.sihosp@gmail.com)

*The information transmitted in this e-mail is intended only for the person or entity to which it is addressed and may contain confidential and/or privileged material. Any review, retransmission, dissemination or other use of or taking of any action in reliance upon, this information by persons or entities other than the intended recipient is prohibited. If you received this e-mail in error, please contact the sender and delete material from any computer.*

**From:** [Cornelia Haener](#)

**To:** '[Robib Telemedicine](#)'; '[Kathy Fiamma](#)'; '[Paul Heinzelmann](#)'; '[Joseph Kvedar](#)'; '[Rithy Chau](#)'; '[Kruy Lim](#)'

**Cc:** '[Bernie Krisher](#)'; '[Jason Reinhardt](#)'; '[Thero So Nourn](#)'; '[Laurie & Ed Bachrach](#)'

**Sent:** Wednesday, September 03, 2014 2:28 PM

**Subject:** RE: Robib TM Clinic September 2014, Case#5, Preab Thinn, 55F

Dear Sovann,

Thanks for submitting this case. I agree with assessment and plan.

Kind regards

Cornelia

**From:** Tan, Heng Soon, M.D.

**Sent:** Thursday, September 04, 2014 10:55 AM

**To:** Fiamma, Kathleen M.

**Subject:** RE: Robib TM Clinic September 2014, Case#5, Preab Thinn, 55F

She appears to have an enlarged thyroid. One possibility is iodine deficiency with euthyroid goiter. However with the history of hyperthyroidism, she has likely an overactive thyroid. Clinically she may be hyperthyroid with the high pulse rate and low weight. The differential diagnosis is Grave's disease with sustained hyperthyroid symptoms or Hashimoto's subacute thyroiditis with transient hyperthyroid symptoms before becoming hypothyroid later. One should look for clinical evidence to support Grave's disease includes eye changes like proptosis and lid retraction [absent in photo], lid lag or ophthalmoplegia. TSH will be low and free T4 will be higher in both situations. Elevated TPO thyroid autoantibodies could be present in both. Radioactive iodine uptake and thyroid scan will be useful since uptake is increased in Graves and reduced in thyroiditis. The clinical implication of distinguishing the two is that in thyroiditis, symptoms are transient and propranolol could be used to suppress symptoms, while in Grave's disease, besides propranolol for symptom control, methimazole could be used to calm down the gland for 6-24 months while hoping for remission.

Heng Soon Tan, MD

---

**From:** [Robib Telemedicine](#)

**To:** [Paul Heinzelmann](#); [Joseph Kvedar](#); [Rithy Chau](#); [Kruy Lim](#); [Kathy Fiamma](#)

**Cc:** [Bernie Krisher](#); [Jason Reinhardt](#); [Thero So Nourn](#); [Laurie & Ed Bachrach](#)

**Sent:** Wednesday, September 03, 2014 1:59 PM

**Subject:** Robib TM clinic September 2014, Case#6, In Un, 78F

Dear all,

This is case number 6, In Un, 78F and photo.

Best regards,  
Sovann

# Robib Telemedicine Clinic

Sihanouk Hospital Center of HOPE and Center for Connected Health  
Rovieng Commune, Preah Vihear Province, Cambodia

## History and Physical



**Name/Age/Sex/Village:** In Un, 78F (Samrith Village)

**Chief Complaint (CC):** Palpitation x 3 years

**History of Present Illness (HPI):** 78F, farmer, presented with symptoms of palpitation (heart beating so fast), HA, neck tension but denied dizziness, vertigo, syncope, diaphoresis. She went to consult in local health center, BP: 160/? and advised to buy antihypertensive. She bought Nifedipine 20mg 1t po qd and traditional medicine. She has had BP check and it was 140 to 160mmHg systolic and the above symptoms still presented so she came to us for help.

**Past Medical History (PMH):** Unremarkable

**Family History:** No family member with HTN, DMII or PTB

**Social History:** No cig smoking; drinking alcohol few litters after delivered the baby, 7 children

**Current Medications:**

1. Nifedipine 20mg 1t po qd

**Allergies:** NKDA

**Review of Systems (ROS):** 5 months symptoms of epigastric pain, burning sensation during hungry, radiation to the back, she never took any medicine for that, no vomiting, no bloody/black stool.

**PE:**

**Vital sign:** BP: 161/77 (both arms) P: 65 R: 18 T: 36.0°C Wt: 45Kg

**General:** look stable

**HEENT:** No oropharyngeal lesion, pink conjunctiva, no thyroid enlargement, no neck LN palpable, no JVD

**Chest:** CTA bilaterally, no rales, no rhonchi; Heart: RRR, no murmur

**Abd:** Soft, no tender, no distension, (+) BS, no HSM, no surgical scar

**Extremities/Skin:** No legs edema, no skin lesion

**MS/Neuro:** MS +5/5, motor and sensory intact, DTRs +2/4, normal gait



**Lab/study:**

RBS: 121mg/dl

U/A: no glucose, no blood, no protein, no leukocyte

**Assessment:**

1. HTN
2. Dyspepsia

**Plan:**

1. Stop Nifedipine and Start HCTZ 25mg 1t po qd
2. Ranitidine 150mg 1t po qhs for one month
3. Mebendazole 500mg 1t po qhs once
4. Do regular exercise
5. Draw blood for Electrolyte, BUN, Creat, Transaminase at SHCH

Labs available locally: Hemoglobin, UA, Glucose, Stool Occult Blood, and Pregnancy Test

**Specific Comments/Questions for Consultants: Do you agree with my assessment and plan?**

**Examined by: Nurse Sovann Peng**

**Date: September 3, 2014**

Please send all replies to [robibtelemed@gmail.com](mailto:robibtelemed@gmail.com) and cc: to [rithychau.sihosp@gmail.com](mailto:rithychau.sihosp@gmail.com)

*The information transmitted in this e-mail is intended only for the person or entity to which it is addressed and may contain confidential and/or privileged material. Any review, retransmission, dissemination or other use of or taking of any action in reliance upon, this information by persons or entities other than the intended recipient is prohibited. If you received this e-mail in error, please contact the sender and delete material from any computer.*

**No answer replied**

---

**From:** [Robib Telemedicine](#)

**To:** [Joseph Kvedar](#) ; [Rithy Chau](#) ; [Kruy Lim](#) ; [Kathy Fiamma](#) ; [Paul Heinzelmann](#)

**Cc:** [Bernie Krisher](#) ; [Jason Reinhardt](#) ; [Thero So Nourn](#) ; [Laurie & Ed Bachrach](#)

**Sent:** Wednesday, September 03, 2014 2:04 PM

**Subject:** Robib TM Clinci September 2014, Case#7, Puth Nem, 72F

Dear all,

This is the last case for Robib TM clinic September 2014, Puth Nem, 72F and photo. Please reply to the cases before Thursday afternoon then the treatment plan can be made accordingly for the patient treatment that afternoon.

Thank you very much for your cooperation and support in this project.

Best regards,  
Sovann

# Robib Telemedicine Clinic

Sihanouk Hospital Center of HOPE and Center for Connected Health  
Rovieng Commune, Preah Vihear Province, Cambodia

## History and Physical



**Name/Age/Sex/Village:** Puth Nem, 72F (Samrith Village)

**Chief Complaint (CC):** Chest tightness x 2months

**History of Present Illness (HPI):** 72F, farmer, presented with symptoms of chest tightness, retro-sternal burning pain, and burping, radiation to the back but she denied vomiting, hematemesis, bloody/black stool. She got treatment several times from local health center but her symptoms still persisted.

**Past Medical History (PMH):** She was diagnosed with HTN for five years and treated with Nifedipine 20mg 1t po bid but she didn't take it regularly. She got BP check yesterday, it was 197/110mmHg (she didn't take Nifedipine for 2 days). She was advised to take it 1t qd and return for check again today.

**Family History:** No family member with HTN, DMII or PTB

**Social History:** No cig smoking; no EtOH

**Current Medications:**

1. Nifedipine 20mg 1t po qd

**Allergies:** NKDA

**Review of Systems (ROS):** No fever, no cough, no dizziness, no diaphoresis, no orthopnea, no edema.

**PE:**

**Vital sign:** BP: 118/79 P: 94 R: 18 T: 36.4°C Wt: 35Kg

**General:** look stable

**HEENT:** No oropharyngeal lesion, pink conjunctiva, no thyroid enlargement, no neck LN palpable, no JVD

**Chest:** CTA bilaterally, no rales, no rhonchi; Heart: RRR, no murmur

**Abd:** Soft, no tender, no distension, (+) BS, no HSM, no surgical scar

**Extremities/Skin:** No legs edema, no skin lesion

**MS/Neuro:** MS +5/5, motor and sensory intact, DTRs +2/4, normal gait

**Lab/study:**

RBS: 120mg/dl

U/A: protein 1+

**Assessment:**

1. GERD
2. HTN (history)

**Plan:**

1. Omeprazole 20mg 1t po qhs for 1 month
2. Metoclopramide 10mg 1t po qhs for 10d
3. Mebendazole 500mg 1t po qhs once
4. Nifedipine 20mg 1t po qd
5. GERD prevention education
6. Do regular exercise
7. Draw blood for Electrolyte, BUN, Creat, Transaminase at SHCH

Labs available locally: Hemoglobin, UA, Glucose, Stool Occult Blood, and Pregnancy Test

**Specific Comments/Questions for Consultants: Do you agree with my assessment and plan?**

**Examined by: Nurse Sovann Peng**

**Date: September 3, 2014**

Please send all replies to [robibtelemed@gmail.com](mailto:robibtelemed@gmail.com) and cc: to [rithychau.sihosp@gmail.com](mailto:rithychau.sihosp@gmail.com)

*The information transmitted in this e-mail is intended only for the person or entity to which it is addressed and may contain confidential and/or privileged material. Any review, retransmission, dissemination or other use of or taking of any action in reliance upon, this information by persons or entities other than the intended recipient is prohibited. If you received this e-mail in error, please contact the sender and delete material from any computer.*

**From:** [Cusick, Paul S., M.D.](mailto:Cusick, Paul S., M.D.)

**To:** [Fiamma, Kathleen M.](mailto:Fiamma, Kathleen M.) ; ['robibtelemed@gmail.com'](mailto:'robibtelemed@gmail.com')

**Cc:** ['rithychau.sihosp@gmail.com'](mailto:'rithychau.sihosp@gmail.com')

**Sent:** Friday, September 05, 2014 11:46 PM

**Subject:** RE: Robib TM Clinic September 2014, Case#7, Puth Nem, 72F

Thank you for the chance to consult.

These symptoms symptoms worse with exertion?

This certainly could be gastroesophageal reflux disease. However, the symptoms are worse with activity, the differential should be expanded to include coronary heart disease or aorta disease.

If she does not respond to omeprazole and treatments prescribed. I would refer her to a regional Health Center for evaluation of her heart.

Thank you so much.

---

# Thursday, September 4, 2014

---

## Follow-up Report for Robib TM Clinic

There were 7 new patients seen during this month Robib TM Clinic, and other 54 patients came for brief consult and medication refills, and 42 new patients seen by PA Rithy for minor problem without sending data. The data of all 7 cases were transmitted and received replies from both Phnom Penh and Boston. Per advice sent by CCH/MGH in Boston and Phnom Penh Sihanouk Hospital Center of HOPE, the following patients were managed and treated as follows:

**NOTE:** [Please note that some blood works was drawn and done at SHCH at no cost and others including studies such as x-rays, U/S, EKG, etc. were done at Kompong Thom Referral Hospital with patients paying on their own. Robib TM clinic **STILL** pays for transportation, accommodation, and other expenses for the patients visiting the clinic **IF** they are from Thnout Malou Village. For those patients who were seen at SHCH previously and remained stable with medications, the clinic will continue to provide them with appropriate medications from SHCH at no cost for the duration of their illnesses or while supplies lasted. The clinic still provided free medications for all "poor" patients. Some patients may be listed below if they came by for refills of medications.]

### Treatment Plan for Robib Telemedicic Clinic September 2014

#### 1. Pheng Sopheara, 16M (Bos Pey Village)

##### Diagnosis:

1. Infected wound on left ear lobule
2. Cellulitis

##### Treatment:

1. Augmentin 625mg 1t po tid x 7days (#21)
2. Ibuprofen 200mg 3t po tid for 5days (#40)
3. Clean the wound with NSS qd

#### 2. Chum Thet, 74F (Somrith Village)

##### Diagnosis:

1. Goiter
2. HTN

##### Treatment:

1. HCTZ 25mg 1t po qd (#70)
2. Do regular exercise, eat low fats diet
3. Draw blood for Lyte, Creat, TSH and Free T4 at SHCH

##### Lab result on September 5, 2014

Na	=133	[135 - 145]
K	=4.6	[3.5 - 5.0]
Cl	=104	[95 - 110]
Creat	=112	[44 - 80]
TSH	=2.86	[0.27 - 4.20]
Free T4	=15.24	[12.0 - 22.0]

#### 3. Em Vin, 56F (Koh Pon Village)

##### Diagnosis:

1. Goiter

2. Osteoarthritis

**Treatment:**

1. Propranolol 40mg 1/4t po bid (#30)
2. Paracetamol 500mg 1-2tab po qid prn pain (#30)
3. Draw blood for TSH and Free T4 at SHCH
4. Do regular exercise, eat low fats diet

**Lab result on September 5, 2014**

TSH = <0.005 [0.27 - 4.20]  
Free T4 = >100 [12.0 - 22.0]

**Note after lab test resulted:** Carbimazole 5mg 2t po tid

**4. Kong Keum, 78M (Rovieng Tbong Village)**

**Diagnosis:**

1. CHF
2. Pleural effusion

**Treatment:**

1. Keep the same above treatment
2. Drink only 1000 – 1500mL water per day
3. Refer to Phnom Penh tomorrow for further evaluation and management

**5. Preab Thinn, 55F (Sre Thom Village)**

**Diagnosis:**

1. Diffuse goiter

**Treatment:**

1. Propranolol 40mg 1/4t po bid (#30)
2. Draw blood for TSH and Free T4 at SHCH

**Lab result on September 5, 2014**

TSH = 0.41 [0.27 - 4.20]  
Free T4 = 16.69 [12.0 - 22.0]

**6. In Un, 78F (Samrith Village)**

**Diagnosis:**

1. HTN
2. Dyspepsia

**Treatment:**

1. HCTZ 25mg 1t po qd (#70)
2. Ranitidine 150mg 1t po qhs for one month (#30)
3. Mebendazole 500mg 1t po qhs once (#1)
4. Do regular exercise
5. Draw blood for Electrolyte, BUN, Creat, Transaminase at SHCH

**Lab result on September 5, 2014**

Na = 136 [135 - 145]  
K = 3.9 [3.5 - 5.0]  
Cl = 108 [95 - 110]  
BUN = 4.1 [<8.3]  
Creat = 103 [44 - 80]  
AST = 28 [<32]  
ALT = 14 [<33]

## 7. Puth Nem, 72F (Samrith Village)

### Diagnosis:

1. GERD
2. HTN

### Treatment:

1. Omeprazole 20mg 1t po qhs for 1month (#30)
2. Metoclopramide 10mg 1t po qhs for 10d (#10)
3. Mebendazole 500mg 1t po qhs once (#1)
4. Nifedipine 20mg 1t po qd (buy)
5. GERD prevention education
6. Do regular exercise
7. Draw blood for Electrolyte, BUN, Creat, Transaminase at SHCH

### Lab result on September 5, 2014

Na	=135	[135 - 145]
K	=3.1	[3.5 - 5.0]
Cl	=105	[95 - 110]
BUN	=5.9	[<8.3]
Creat	=112	[44 - 80]
AST	=32	[<32]
ALT	=1	[<33]

## Patients who come for brief consult and refill medicine

### 1. Chan Kome, 7M (Bang Korn Village)

#### Diagnosis:

1. Epilepsy post trauma

#### Treatment:

1. Carbamazepine 200mg 1/2t po qd for two months (#35)
2. MTV 1t po qd for two months (#60)
3. Draw blood for Lyte, Creatinine, Transaminase at SHCH

### Lab result on September 5, 2014

Na	=134	[135 - 145]
K	=3.7	[3.5 - 5.0]
Cl	=107	[95 - 110]
Creat	=68	[53 - 97]
AST	=32	[<40]
ALT	=24	[<41]

### 2. Chan Oeung, 64M (Sangke Roang Village)

#### Diagnosis:

1. Osteoarthritis
2. Gouty arthritis
3. Renal insufficiency
4. HTN

#### Treatment:

1. Allopurinol 100mg 2t po qd for two months (#120)
2. Paracetamol 500mg 1-2t po qid prn pain (#40)
3. Losartan 50mg 1t po bid for two months (#120)

### 3. Chan Ourn, 65F (Bakdoang Village)

#### Diagnosis:

1. DMII



**Treatment:**

1. Metformin 500mg 1t po bid for two months (#120)
2. Draw blood for CBC, Malaria smear, Lyte, Creatinine, Glucose, Transaminase, HbA1C, and TSH at SHCH

**Lab result on September 5, 2014**

WBC	=5.0	[4 - 11x10 <sup>9</sup> /L]	Na	=129	[135 - 145]
RBC	=4.7	[3.9 - 5.5x10 <sup>12</sup> /L]	K	=2.6	[3.5 - 5.0]
Hb	=11.6	[12.0 - 15.0g/dL]	Cl	=98	[95 - 110]
Ht	=35	[35 - 47%]	Creat	=116	[44 - 80]
MCV	=76	[80 - 100fl]	Gluc	=13.4	[4.1 - 6.1]
MCH	=25	[25 - 35pg]	AST	=20	[<32]
MHCH	=33	[30 - 37%]	ALT	=15	[<33]
Plt	=356	[150 - 450x10 <sup>9</sup> /L]	HbA1C	=8.5	[4.0 - 6.0]
Lymph	=1.6	[1.00 - 4.00x10 <sup>9</sup> /L]	TSH	=1.36	[0.27 - 4.20]
Mono	=0.6	[0.10 - 1.00x10 <sup>9</sup> /L]	Malaria	= Negative	
Neut	=2.8	[1.80 - 7.50x10 <sup>9</sup> /L]			

**4. Chan Vy, 54F (Taing Treuk Village)****Diagnosis:**

1. DMII
2. HTN
3. Left side stroke with right side weakness

**Treatment:**

1. Metformin 500mg 2t po bid for two months (#120)
2. Lisinopril 5mg 1t po qd for two months (#60)
3. ASA 100mg 1t po qd for two months (#60)

**5. Duch Channy, 52M (Taing Treuk Village)****Diagnosis:**

1. DMII

**Treatment:**

1. Metformin 500mg 2t po bid for two months (buy)
2. Glibenclamide 5mg 2t po bid for two months (#120)
3. ASA 100mg 1t po qd for two months (#60)

**6. Eam Neut, 62F (Taing Treuk)****Diagnosis**

1. HTN

**Treatment**

1. Amlodipine 10mg 1t po qd for four months (#60)

**7. Keum Heng, 47F (Koh Lourng Village)****Diagnosis:**

1. Hyperthyroidism
2. HTN

**Treatment:**

1. Carbimazole 5mg 1/2t po tid for two months (buy)
2. Propranolol 40mg 2t po bid for two months (#80)
3. Captopril 25mg 1t po bid for two months (buy)
4. Draw blood for Free T4 at SHCH

**Lab result on September 5, 2014**

Free T4=18.22 [12.0 - 22.0]

**8. Kham Sary, 51M (Thnal Koang Village)**

**Diagnosis:**

1. DMII

**Treatment:**

1. Metformin 500mg 2t po bid for two months (#100)
2. Glibenclamide 5mg 1t bid two months (#80)
3. Captopril 25mg 1/2t bid two months (buy)
4. Draw blood for Glucose, and HbA1C at SHCH

**Lab result on September 5, 2014**

Gluc	=9.0	[4.1 - 6.1]
HbA1C	=8.7	[4.8 - 5.9]

**9. Kin Sok, 35F (Bos Pey Village)**

**Diagnosis:**

1. Hyperthyroidism

**Treatment:**

1. Carbimazole 5mg 2t po tid for two months (#80)

**10. Kin Yin, 37F (Bos Pey Village)**

**Diagnosis:**

1. Hyperthyroidism

**Treatment:**

1. Carbimazole 5mg 2t po tid for two months (buy)
2. Propranolol 40mg 1/2t po bid for two months (#30)

**11. Kouch Be, 85M (Thnout Malou Village)**

**Diagnosis:**

1. Eczema?
2. HTN
3. COPD

**Treatment:**

1. Cetirizine 10mg 1t po qhs (buy)
2. Use moisturizing shampoo or soap for shower
3. Avoid sun exposure
4. Amlodipine 10mg 1/2t po qd (#30)
5. Salbutamol inhaler 2puffs bid prn (#1)

**12. Mar Thean, 56M (Rom Chek Village)**

**Diagnosis:**

1. DMII

**Treatment:**

1. Metformin 500mg 3t po qAM, 2t po qPM for four months (#130)
2. Glibenclamide 5mg 2t po bid for four months (#200)
3. ASA 100mg 1t po qd for four months (#80)

**13. Meas Ream, 88F (Taing Treuk Village)**

**Diagnosis:**

1. HTN
2. Left side stroke with right side weakness
3. Dyspepsia

**Treatment:**

1. HCTZ 50mg 1/2t po qd for four months (#60)

2. Paracetamol 500mg 1t po qid for four months (#30)
3. Ranitidine 150mg 1t po qhs for one month (#30)

#### 14. Nung Chhun, 76F (Ta Tong Village)

##### Diagnosis:

1. DMII
2. HTN

##### Treatment:

1. Metformin 500mg 11/2t po bid for two months (#100)
2. Glibenclamide 5mg 1t po bid for two months (buy)
3. Captopril 25mg 1t po tid for two months (buy)
4. Amlodipine 5mg 1t po qd for two months (buy)
5. ASA 100mg 1t po qd for two months (#60)
6. Draw blood for Creatinine, Glucose, HbA1C at SHCH

##### Lab result on September 5, 2014

Creat	=177	[44 - 80]
Gluc	=8.3	[4.1 - 6.1]
HbA1C	=7.7	[4.8 - 5.9]

#### 15. Pech Huy Keung, 51M (Rovieng Cheung Village)

##### Diagnosis:

1. DMII
2. HTN

##### Treatment:

1. Glibenclamide 5mg 1t po bid for two months (#120)
2. Metformin 500mg 3t po qAM and 2t po qPM for two months (#100)
3. Captopril 25mg 1t po bid for two months (buy)
4. Amlodipine 10mg 1/2t po qd for two months (#30)
5. ASA 100mg 1t po qd for two months (#60)
6. Draw blood for Glucose, and HbA1C at SHCH

##### Lab result on September 5, 2014

Gluc	=6.4	[4.1 - 6.1]
HbA1C	=7.8	[4.8 - 5.9]

#### 16. Prak Nai, 45M (Samrith Village)

##### Diagnosis:

1. DMII

##### Treatment:

1. Metformin 500mg 1t po bid for two months (#80)
2. ASA 100mg 1t po qd for two months (#60)
3. Review on diabetic diet, regular exercise and foot care

#### 17. Prum Norn, 59F (Thnout Malou Village)

##### Diagnosis:

1. Liver cirrhosis with PHTN
2. HTN
3. Hypertrophic Cardiomyopathy
4. Renal Failure
5. Gouty Arthritis

##### Treatment:

1. Spironolactone 25mg 1t po qd for two months (#60)
2. Furosemide 40mg 1/2t po bid for two months (#60)

3. Propranolol 40mg 1/2t po bid for two months (#35)
4. Paracetamol 500mg 1t po qid prn pain two months (#30)
5. Allopurinol 100mg 1t po qd for two months (#60)
6. FeSO4/Folate 200/0.4mg 1t po qd for two months (#60)

**18. Prum Pri, 45M (Rom Chek Village)**

**Diagnosis:**

1. Hyperthyroidism
2. HTN

**Treatment:**

1. Carbimazole 5mg 1t po bid for two months (buy)
2. Propranolol 40mg 1/2t po bid for two months (#30)

**19. Ream Sim, 58F (Thnal Keng Village)**

**Diagnosis:**

1. HTN
2. DMII
3. Osteoarthritis

**Treatment:**

1. Metformin 500mg 2t po bid for two months (#100)
2. Lorsatan 100mg 1/2t po bid for two months (#65)
3. Atenolol 50mg 1t po qd for two months (#60)
4. ASA 100mg 1t po qd for two months (#60)
5. Review on diabetic diet, and foot care

**20. Sam Khim, 50F (Taing Treuk Village)**

**Diagnosis:**

1. DMII

**Treatment:**

1. Metformin 500mg 2t po bid for two months (#100)
2. Glibenclamide 5mg 2t po bid for two months (#200)
3. Pioglitazone 15mg 1t po qd for two months (buy)
4. Captopril 25mg 1/2t po bid for two months (buy)
5. Draw blood for Glucose, and HbA1C at SHCH

**Lab result on September 5, 2014**

Gluc	=7.7	[4.1 - 6.1]
HbA1C	=14.1	[4.8 - 5.9]

**21. Sann Phen, 58M (Romchek Village)**

**Diagnosis:**

1. PTB
2. DMII

**Treatment:**

1. Continue TB treatment at local health center
2. Glibenclamide 5mg 1t po bid for two months (#100)
3. Review on diabetic diet and foot care

**22. Seng Yom, 45F (Damnak Chen Village)**

**Diagnosis:**

1. Mod-severe MR/TR, mild AR with normal EF
2. Hyperthyroidism

**Treatment:**

1. Digoxin 0.25mg 1t po qd for two months (#60)

2. Propranolol 40mg 1/4t po qd for two months (#20)
3. Furosemide 40mg 1/2t qd for two months (#30)
4. ASA 100mg 1t qd for two months (#60)
5. Carbimazole 5mg 1t po tid for two months (#90)
6. FeSO4/Folate 200/0.4mg 1t po qd for two months (#60)

**23. So Chhorm, 77M (Thkeng Village)**

**Diagnosis:**

1. HTN

**Treatment:**

1. Amlodipine 5mg 1t po qd for two months (buy)
2. HCTZ 50mg 1/2t po qd for two months (#35)
3. Do regular exercise

**24. Teav Vandy, 67F (Rovieng Cheung Village)**

**Diagnosis:**

1. HTN

**Treatment:**

1. HCTZ 50mg 1/2t po qd for four months (# 60)

**25. Thourn Nhorn, 42F (Svay Pat Village)**

**Diagnosis:**

1. DMII
2. HTN

**Treatment:**

1. Metformin 500mg 1t po bid for two months (#80)
2. Glibemclamide 5mg 1t po bid for two months (#100)
3. Captopril 25mg 1/2t po bid for two months (buy)
4. Draw blood for Glucose and HbA1C at SHCH

**Lab result on September 5, 2014**

Gluc	=8.7	[4.1 - 6.1]
HbA1C	=7.1	[4.8 – 5.9]

**26. Un Chhorn, 47M (Taing Treuk Village)**

**Diagnosis:**

1. DMII
2. HTN

**Treatment:**

1. Glibenclamide 5mg 1t po bid for two months (#60)
2. Metformin 500mg 2t po bid for two months (#90)
3. Captopril 25mg 1/2t po bid for two months (buy)

**27. Un Rady, 51M (Rom Chek Village)**

**Diagnosis:**

1. DMII
2. HTN

**Treatment:**

1. Glibenclamide 5mg 1t po bid for two months (#120)
2. Amlodipine 5mg 1t po qd for two months (buy)
3. ASA 100mg 1t po qd for two months (#60)
4. Draw blood for Creatinine, Glucose, and HbA1C at SHCH

**Lab result on September 5, 2014**

Creat =240 [53 - 97]  
Gluc =5.9 [4.1 - 6.1]  
HbA1C =6.0 [4.8 - 5.9]

**28. Uy Noang, 62M (Thnout Malou Village)**

**Diagnosis:**

1. DMII
2. HTN

**Treatment:**

1. Glibenclamide 5mg 2t po bid for four months (#200)
2. Metformine 500mg 2t po bid for four months (#120)
3. Pioglitazone 15mg 1t po qd for four months (buy)
4. Enalapril 10mg 1/2t po qd for four months (#60)

**29. Yin Kheum, 55F (Chhnourn Village)**

**Diagnosis:**

1. HTN

**Treatment:**

1. HCTZ 50mg 1/2t po qd for two months (#35)

**30. Yun Yeung, 75M (Doang Village)**

**Diagnosis:**

1. HTN

**Treatment:**

1. HCTZ 50mg 1/2t po qd for four months (#65)

**31. Chan Khem, 63F (Taing Treuk Village)**

**Diagnosis:**

1. HTN

**Treatment:**

1. HCTZ 50mg 1/2t po qd for four months (#60)

**32. Chhim Bon, 73F (Taing Treuk Village)**

**Diagnosis:**

1. HTN

**Treatment:**

1. HCTZ 50mg 1/2t po qd for four months (#60)
2. Paracetamol 500mg 1t po qid for four months (#30)

**33. Chum Chandy, 55F (Ta Tong Village)**

**Diagnosis:**

1. DMII

**Treatment:**

1. Metformin 500mg 1t po bid for two months (#60)
2. ASA 100mg 1t po qd for two months (#40)
3. Draw blood for Glucose, and HbA1C at SHCH

**Lab result on September 5, 2014**

Gluc =10.1 [4.1 - 6.1]  
HbA1C =8.7 [4.8 - 5.9]

**34. Heng Chan Ty, 52F (Ta Tong Village)**

**Diagnosis:**



1. Hyperthyroidism
2. Urticaria

**Treatment:**

1. Carbimazole 5mg 2t po bid for two months (buy)
2. Propranolol 40mg ¼ t po qd for two months (#20)
3. Mebendazole 500mg 1t po qhs once (#1)
4. Cetirizine 10mg 1t po qhs for two months (#30)

**35. Heng Naiseang, 64F (Taing Treuk Village)**

**Diagnosis:**

1. HTN

**Treatment:**

1. HCTZ 50mg 1t po qd for four months (#120)
2. Captopril 25mg 1/2t po bid for four months (buy)

**36. Kong Soeun, 31M (Backdoang Village)**

**Diagnosis:**

1. DMII

**Treatment:**

1. Glibenclamide 5mg 1t po bid for four months (#150)
2. Captopril 25mg 1/4t po bid for four months (buy)

**37. Kul Keung, 68F (Taing Treuk Village)**

**Diagnosis:**

1. HTN
2. DMII with PNP

**Treatment:**

1. Glibenclamide 5mg 1t po bid for four months (buy)
2. Metformin 500mg 1t po bid for four months (#120)
3. Captopril 25mg 1t po bid for four months (buy)
4. ASA 100mg 1t po qd for four months (buy)
5. Amitriptylin 25mg 1/4t po qhs for four months (#30)

**38. Kun Ban, 57M (Thnal Keng Village)**

**Diagnosis:**

1. DMII

**Treatment:**

1. Metformin 500mg 1t po bid for four months (#130)
2. Glibenclamide 5mg 1t po bid for four months (#150)
3. ASA 300mg 1/4t po qd for four months (buy)
4. Captopril 25mg 1/4t po bid for four months (buy)

**39. Meas Lam Phy, 61M (Thnout Malou Village)**

**Diagnosis:**

1. DMII

**Treatment:**

1. Metformin 500mg 1t po bid for two months (#70)
2. Captopril 25mg 1/4t po qd for two months (buy)
3. ASA 100mg 1t po qd for two months (#60)
4. Draw blood for Creatinine, Glucose, and HbA1C at SHCH

**Lab result on September 5, 2014**

Creat =94 [53 - 97]

Gluc =9.1 [4.1 - 6.1]  
HbA1C =8.1 [4.8 - 5.9]

**40. Moeung Rin, 67F (Taing Treuk Village)**

**Diagnosis:**

1. HTN
2. Osteoarthritis
3. Eczema

**Treatment:**

1. HCTZ 50mg 1/2t po qd for four months (#60)
2. Atenolol 50mg 1/2t po qd for four months (buy)
3. Paracetamol 500mg 1-2t po qid prn pain for four months (#40)
4. Desoximehtasone cream apply bid (#1)

**41. Moeung Srey, 50F (Thnout Malou Village)**

**Diagnosis**

1. HTN
2. Dyspepsia

**Treatment**

1. Amlodipine 10mg 1/2t po qd for four months (#30)
2. Ranitidine 150mg 1t po qhs for one month (#30)

**42. Ny Ngek, 59F (Svay Pat Village)**

**Diagnosis:**

1. DMII with PNP
2. HTN

**Treatment:**

1. Metformin 500mg 1t bid for two months (#120)
2. Captopril 25mg 1t bid for two months (buy)
3. ASA 100mg 1t po qd for two months (#60)
4. Draw blood for Creatinine, Glucose, Tot chole and HbA1C at SHCH

**Lab result on September 5, 2014**

Creat =84 [44 - 80]  
Gluc =6.2 [4.1 - 6.1]  
T. Chol =10.9 [<5.7]  
HbA1C =6.9 [4.8 - 5.9]

**43. Prum Chean, 50F (Sangke Roang Village)**

**Diagnosis:**

1. DMII

**Treatment:**

1. Metformin 500mg 2t po bid for two months (#100)
2. ASA 100mg 1t po qd for two months (#60)

**44. Prum Vandy, 50F (Taing Treuk Village)**

**Diagnosis:**

1. Hyperthyroidism

**Treatment:**

1. Carbimazole 5mg 1t po qd for two months (buy)
2. Propranolol 40mg 1/4t po bid for two months (#30)
3. Draw blood for Free T4 at SHCH

**Lab result on September 5, 2014**

Free T4=**26.27** [12.0 - 22.0]

**45. Ros Yeth, 60M (Thnout Malou Village)**

**Diagnosis:**

1. DMII
2. HTN

**Treatment:**

1. Glibenclamide 5mg 2t po bid for four months (#200)
2. Metformin 500mg 1t po bid for four months (#130)
3. Enalapril 10mg 1/2t po qd for four months (#60)
4. Amlodipine 5mg 1t po qd for four months (buy)

**46. Sao Ky, 75F (Thnout Malou Village)**

**Diagnosis**

1. HTN

**Treatment**

1. HCTZ 50mg 1/2t po qd for four months (#60)

**47. Sao Phal, 66F (Thnout Malou Village)**

**Diagnosis:**

1. HTN
2. Anxiety
3. Renal insufficiency

**Treatment:**

1. Enalapril 10mg 1/4t po qd for four months (#30)
2. Amitriptylin 25mg 1/4t po qhs for four months (#30)
3. MTV 1t po qd for four months (#120)
4. Paracetamol 500mg 1t qid prn HA/fever for four months (#40)

**48. Sourn Chroch, 40M (Sre Village, Reab Roy)**

**Diagnosis:**

1. DMII

**Treatment:**

1. Metformin 500mg 1t po bid for two months (#100)
2. Glibenclamide 5mg 1/2t po bid for two months (#60)
3. ASA 100mg 1t po qd for two months (#60)
4. Draw blood for Glucose and HbA1C at SHCH

**Lab result on September 5, 2014**

Gluc	=4.4	[4.1 - 6.1]
HbA1C	=6.2	[4.8 - 5.9]

**49. Srey Ry, 63M (Rovieng Cheung Village)**

**Diagnosis:**

1. HTN

**Treatment:**

1. HCTZ 50mg 1/2t po qd for four months (#60)

**50. Srey Thouk, 60F (Taing Treuk Village)**

**Diagnosis:**

1. HTN

**Treatment:**

1. Atenolol 50mg 1/2t po qd for four months (#30)
2. ASA 100mg 1t po qd for four months (#90)

**51. Svay Tevy, 48F (Sre Thom Village)**

**Diagnosis:**

1. DMII
2. HTN

**Treatment:**

1. Glibenclamide 5mg 2t po bid for two months (#150)
2. Metformin 500mg 3t qAM and 2t po qPM for two months (buy)
3. Pioglitazone 15mg 1t po qd for two months (buy)
4. Captopril 25mg 1t po bid for two months (buy)
5. ASA 100mg 1t po qd for two months (#60)

**52. Tann Sou Hoang, 53F (Rovieng Cheung Village)**

**Diagnosis:**

1. DMII
2. HTN

**Treatment:**

1. Metformin 500mg 2t po bid for four months (#130)
2. Captopril 25mg 1/2t po bid for four months (buy)
3. ASA 300mg 1/4t po qd for four months (buy)

**53. Un Chhourn, 44M (Taing Treuk Village)**

**Diagnosis:**

1. DMII
2. HTN

**Treatment:**

1. Glibenclamide 5mg 1t po bid for four months (buy)
2. Metformin 500mg 1t po qAM for four months (#100)
3. Captopril 25mg 1/2t po bid for four months (buy)
4. ASA 100mg 1t po qd for four months (#80)

**54. Thorng Khun, 43F (Thnout Malou Village)**

**Diagnosis:**

1. Hyperthyroidism

**Treatment:**

1. Draw blood for Free T4 at SHCH

**Lab result on September 5, 2014**

Free T4=**65.41** [12.0 - 22.0]

---

**The next Robib TM Clinic will be held on  
November 10 -14, 2014**